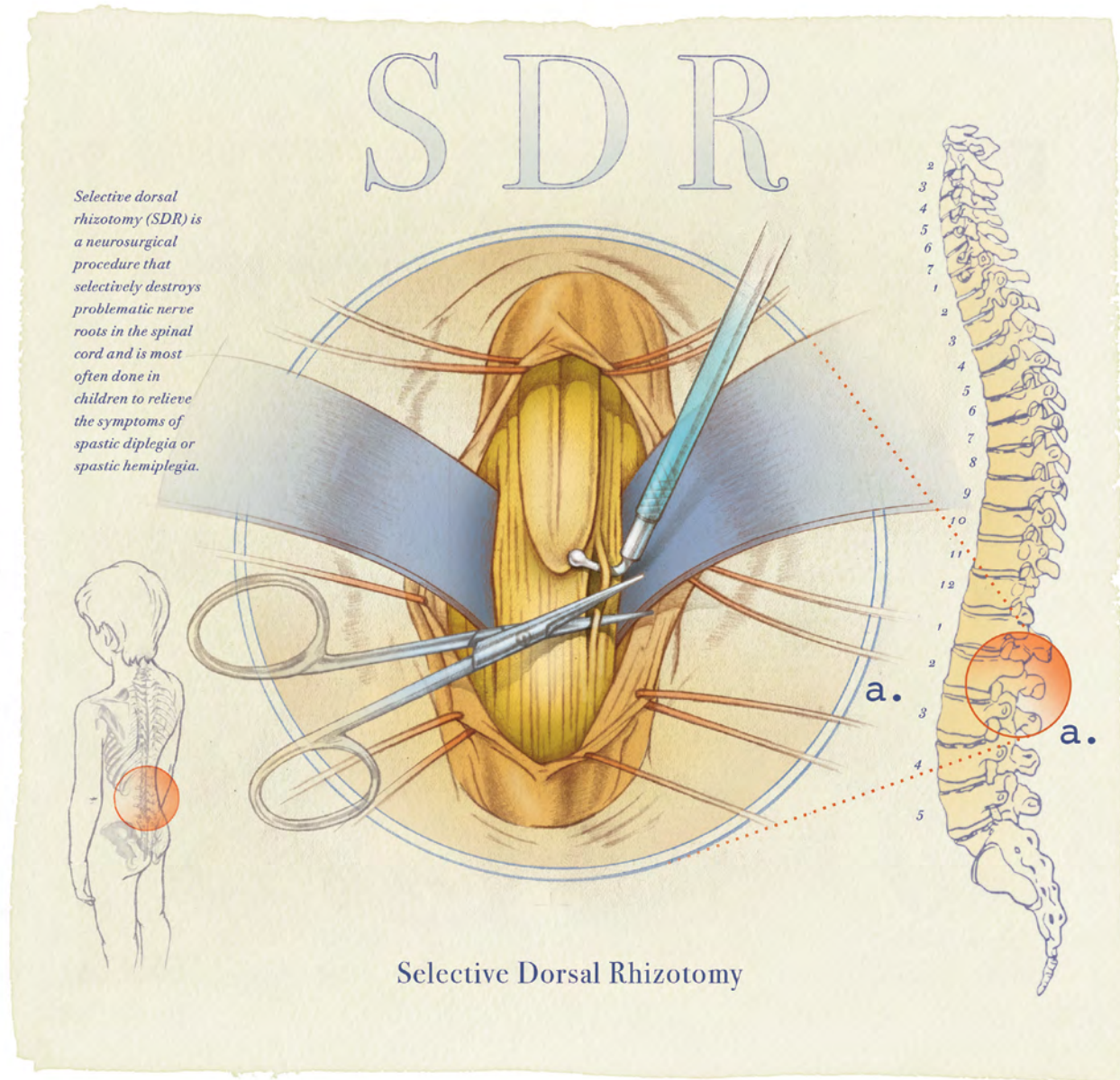


CHILDREN'S MEMORIAL HERMANN HOSPITAL  
 PEDIATRIC NEUROSCIENCE  
**JOURNAL**

A PUBLICATION OF CHILDREN'S MEMORIAL HERMANN HOSPITAL AND MCGOVERN MEDICAL SCHOOL AT UTHealth



# IN THIS ISSUE

---

**01** True Stories of Strength, Courage and Perseverance

## PEDIATRIC SPASTICITY MANAGEMENT

**02** Darius Sonia: The Perfect Candidate for Selective Dorsal Rhizotomy

**04** Inside the Texas Comprehensive Spasticity Center

**05** A Fresh Start for Cristian Serrato: Deep Brain Stimulation Transforms a Life

**07** Using Sophisticated Brain-imaging Techniques to Help Make the Treatment Decision for Patients with Spastic Cerebral Palsy

## INTRACTABLE EPILEPSY

**08** Toward a New Paradigm for the Treatment of Intractable Epilepsy

## BRAIN TUMOR TREATMENT

**10** Methotrexate Infusion Directly into the Fourth Ventricle in Children with Malignant Fourth Ventricular Brain Tumors

**12** Riley Lentz: No Stone Unturned

**13** Detecting Pediatric Brain Tumors

## CLINICAL TRIALS FOR RARE DISORDERS

**14** Early Biomarkers of Autism Spectrum Disorder in Infants with Tuberous Sclerosis Complex

Continuation Study for Individuals Diagnosed with Autism Spectrum Disorders and Tuberous Sclerosis Complex

**15** Intra Erythrocyte Dexamethasone in the Treatment of Ataxia Telangiectasia

## NEWS OF NOTE

**16** Children's Memorial Hermann Hospital and the McGovern Medical School Welcome Dr. Michael Watkins

Dr. David Sandberg Awarded the Inaugural Dr. Marnie Rose Professorship in Pediatric Neurosurgery

**17** Dr. Manish Shah Named to *Houston Business Journal's* 40 Under 40

**18** Seven Pediatric Neuroscience Specialists Named to Top Doctors Lists for 2015

**19** SELECTED PUBLICATIONS

# TRUE STORIES *of* STRENGTH, COURAGE *and* PERSEVERANCE

Children are our future. If we give them the tools they need to succeed, including health, their lives will unfold in wonderful, unexpected ways.

In this inaugural issue of the Children's Memorial Hermann Hospital and McGovern Medical School at UTHealth *Pediatric Neuroscience Journal*, we tell the stories of three families who made courageous decisions to improve the lives of their children. We're grateful to Sarah Sonia, the mother of Darius Sonia; Lusi and Guadalupe Serrato, the parents of Cristian Serrato; and Melissa Saban, the mother of Riley Lentz, for sharing their experiences at Children's Memorial Hermann Hospital.

Born seven weeks early, Darius suffered an intraventricular hemorrhage in the first few days of life that left him with spasticity in the lower limbs. A beneficiary of the expertise of Dr. Manish Shah, the leading neurosurgeon in the area for selective dorsal rhizotomy, the eight year old is now taking karate lessons and talking about playing high school football.

Until she was six, Cristian was walking, talking and eating normally. Then one by one, she started losing her developmental milestones. When she presented with rapid onset dystonia-parkinsonism, her multidisciplinary physician team made a bold move to recommend deep brain stimulation, a procedure that changed her life.

After recurrence of her malignant brain tumor (medulloblastoma) despite multiple treatments, Riley was among the first participants enrolled in the phase II clinical trial of direct delivery of methotrexate into the fourth ventricle of the brain, an innovative therapy that minimizes the side effects of chemotherapy by decreasing systemic drug exposure. In January, her mother posted her daughter's positive results on her Facebook page.

Physicians affiliated with Children's Memorial Hermann Hospital, the Memorial Hermann Mischer Neuroscience Institute at the Texas Medical Center and McGovern Medical School are engaged in a broad and intensive research program focused on the mechanisms, treatment and cure of neurological disease and injury. In this issue we report on a team of physicians who believe that the future of epilepsy treatment lies in the study of brain networks using magnetoencephalography (MEG). Other teams focus on clinical trials for rare disorders, including autism spectrum disorder in infants with tuberous sclerosis complex and a new treatment for ataxia telangiectasia, a progressively disabling, life-threatening disease for which no therapy is currently available.

We would like to take this opportunity to congratulate Dr. Manish Shah on being named to the *Houston Business Journal's* 40 Under 40 Class of 2015 and to welcome Dr. Michael Watkins as the newest member of our team of affiliated pediatric physicians. Dr. Watkins focuses his practice on the treatment of epilepsy in children, particularly intractable epilepsy, including the use of magnetoencephalography (MEG) in the evaluation of pediatric patients with medically refractory seizures.

We hope you find the information in our *Pediatric Neuroscience Journal* interesting and useful. If you have questions about our programs, please feel free to contact us directly.

With best wishes,



**DAVID I. SANDBERG, M.D., FAANS, FACS, FAAP**

Director of Pediatric Neurosurgery, Children's Memorial Hermann Hospital and Memorial Hermann Mischer Neuroscience Institute at the Texas Medical Center

Associate Professor, Dr. Mamie Rose Professorship in Pediatric Neurosurgery, Department of Pediatric Surgery and Vivian L. Smith Department of Neurosurgery, McGovern Medical School at UTHealth

Co-director, Pediatric Brain Tumor Program, The University of Texas MD Anderson Cancer Center  
713.500.7370



**IAN J. BUTLER, M.D.**

Professor and Director of Child and Adolescent Neurology, Distinguished Chair in West Syndrome Research, McGovern Medical School at UTHealth  
713.500.7142

# DARIUS SONIA: THE PERFECT CANDIDATE *for* SELECTIVE DORSAL RHIZOTOMY

**A** caring and informed mother, a knowledgeable physical therapist and an expert in the surgical management of spasticity have transformed the life of eight-year-old Darius Sonia.

Born seven weeks early, Darius suffered an intraventricular hemorrhage in the first few days of life – a common occurrence with premature birth. The hemorrhage left him with a single significant deficit: spasticity in the lower limbs.

or four days a week of hour-long therapy sessions after the surgery.”

Selective dorsal rhizotomy (SDR) is a neurosurgical procedure that selectively destroys problematic nerve roots in the spinal cord and is most often done in children to relieve the symptoms of spastic diplegia or spastic hemiplegia. Performed correctly in the right surgical hands, the procedure provides an immediate, permanent reduction in spasticity and offers children who follow a program of intensive postoperative therapy the potential to walk independently within one to two years.

After the ADHD evaluation, Sonia had reservations about starting her son on medication. “I wasn’t sure about it, but it turned out to be a good decision,” she says. “He took it for two years with good results. In the meantime, we changed therapists and I started reconsidering dorsal rhizotomy.”

**“MOST PROVIDERS USE LONGER INCISIONS AND CUT ONLY ABOUT 30 PERCENT OF THE ROOTLETS. EVIDENCE SHOWS THAT THIS APPROACH OFTEN FAILS IN THE LONG TERM, WITH A RETURN OF THE SPASTICITY. WE SEE MANY PATIENTS WITH FAILED RHIZOTOMIES AND UNFORTUNATELY, THERE’S NOTHING WE CAN DO FOR THEM SURGICALLY. IT’S A ONE-SHOT PROCEDURE. IF PARENTS ARE CONSIDERING RHIZOTOMY, WE STRONGLY ENCOURAGE THEM TO BE EVALUATED AT CHILDREN’S MEMORIAL HERMANN HOSPITAL IN HOUSTON.”**

“Darius has been in therapy since he was three months old,” says his mother Sarah Sonia, who moved to Houston from Shreveport, Louisiana, in 2008, a year after her son’s birth. “In therapy he learned to stretch his muscles and improve his range of motion, but eventually the tightness would come back. When he was about five, I started considering a dorsal rhizotomy, which requires a year of intensive physical therapy following the surgery. But a pre-surgery evaluation showed he had ADHD. We didn’t think he could concentrate well enough to do three



**MANISH N. SHAH, M.D.**

*Director, Pediatric Spasticity and Movement Disorder Surgery; Assistant Professor, Department of Pediatric Surgery, McGovern Medical School at UTHealth*

The new therapist was Christine Hill, PT. Hill thought Darius would do well with SDR and suggested they ask for a referral to Manish N. Shah, M.D., who directs the Texas Comprehensive Spasticity Center at McGovern Medical School, Children’s Memorial Hermann Hospital and the Memorial Hermann Mischer Neuroscience Institute at the Texas Medical Center. Fellowship-trained in pediatric neurosurgery, with special expertise in the surgical management of spasticity and dystonia in children, Dr. Shah is the leading neurosurgeon in the area for selective dorsal rhizotomy and also is an expert in pediatric epilepsy, craniofacial surgery and craniocervical spine surgery. He was recruited from Washington University in St. Louis after completing his fellowship at St. Louis Children’s Hospital under world-renowned pediatric neurosurgeon Tae Sung Park, M.D.





“We do selective dorsal rhizotomy with a single incision at one to one-and-a-half levels of the spine and cut 75 to 80 percent of the nerve rootlets,” Dr. Shah says. “Most providers use longer incisions and cut only about 30 percent of the rootlets. Evidence shows that this 30 percent rootlet-cutting approach often fails in the long term, with a return of the spasticity. We see such patients with failed rhizotomies and unfortunately, there’s nothing we can do for them surgically. It’s a one-shot procedure. If

parents are considering rhizotomy, we strongly encourage them to be evaluated at Children’s Memorial Hermann Hospital in Houston.”

Darius was the perfect candidate for SDR, according to well-established criteria for success: the spasticity was limited to his legs, he had good trunk control and no previous orthopedic procedures, he could tolerate physical and occupational therapy and he had strong family support.

In June 2015, Dr. Shah took Darius to the OR, where he performed a one-level

**An intraventricular hemorrhage in the first few days of life left Darius Sonia with spasticity in his legs. Thanks to the surgical skill of Dr. Manish Shah, Darius participates in activities that once seemed unattainable.**

laminectomy and unroofed the spinal canal in the mid-lower back. After exposing the dorsal sensory nerve roots, he divided them into rootlets and tested them one by one, cutting about 75 percent of the most spastic rootlets. The surgery took two and a half hours.



Darius spent 48 hours on bed rest and was up and active immediately afterward. After a four-day stay at Children's Memorial Hermann Hospital, he was transferred to Shriners Hospital for Children in the Texas Medical Center for inpatient rehabilitation. Therapy began as soon as he was admitted.

"When I went to see Darius to remove the bandage a week and a half after surgery, he was already up roaming the hallway in a wheeled walker," says Dr. Shah, who is an assistant professor in the division of Pediatric Neurosurgery at McGovern Medical School and director of pediatric spasticity and movement disorder surgery. "What a sweet kid! He's enthusiastic and adorable and very motivated to walk. We all win the lottery in different ways. He was premature and had the intraventricular hemorrhage, but his mom educated herself about his condition and found excellent therapists. In our experience young patients with a strong desire to succeed and good family support can achieve independent walking."

Darius was released from Shriners Hospital a week earlier than expected. "The surgery was a good decision for him," his mother says. "He always wanted to participate in some kind of sport but because of his balance problems, I never thought he'd be able to. Now he's taking karate, doing kicks and punches, and talking about how he wants to play football and be a quarterback. His muscles are getting stronger and he's doing things he couldn't do before the surgery."

Darius turned eight in August 2015. He continues therapy three times a week and sees Dr. Shah every three months in follow-up, which will continue for at least another year.

"We like to follow patients over time as part of their care team so we can continue to help them improve their mobility," he says. "We're not the kind of practice that operates on kids and discharges them into the wild. We're very committed to the long-term welfare of our patients and their families."

## Inside the Texas Comprehensive Spasticity Center



Like Darius, children with spasticity, movement disorders or cerebral palsy have complex care needs and typically see multiple providers for different opinions before their parents make a treatment decision. In the process

they lose valuable time and, in many cases, suffer irreversible damage. Specialists affiliated with the Texas Comprehensive Spasticity Center aim to end the cycle of referral from specialist to specialist by offering carefully coordinated multidisciplinary care in a single location.

A collaboration of Children's Memorial Hermann Hospital, the Memorial Hermann Mischer Neuroscience Institute at the Texas Medical Center and McGovern Medical School, the Texas Comprehensive Spasticity Center is led by Manish N. Shah, M.D., an assistant professor in the division of Pediatric Neurosurgery and director of pediatric spasticity and movement disorder surgery. The team of affiliated physicians includes a pediatric neurologist who specializes in movement disorders, three pediatric neurosurgeons, pediatric orthopedists and a pediatric physical medicine and rehabilitation specialist, plus physical and occupational therapists, a clinical trial program manager and physician assistants and medical assistants who coordinate care. This multidisciplinary approach ensures the most comprehensive specialized treatment for each patient, beginning with evaluation – observation, videos and medical tests – and continuing through treatment and therapy.

"No other group of specialists in the region sees spasticity patients together for an hour in one room," Dr. Shah says. "We all work together to determine in one session what the child needs, so that parents know exactly what the treatment options are before they leave the Center. This approach saves children years of bouncing from provider to provider with no real treatment decision made. They often need to be seen by three or four specialists. By the time they see all of these providers – and many have long scheduling wait times – the contracture has caused irreversible damage to their joints and muscles. They may need to see an orthopedic surgeon. If they do, we can refer them down the hall. If we determine that they need a new brace, we can refer them to occupational therapy. If a child is a candidate for selective dorsal rhizotomy, we can schedule the surgery and arrange a transfer to Shriners Hospital for Children for inpatient rehabilitation after discharge from acute care. We also ensure that parents have access to home therapy after their stay at Shriners."

"The process we've created fills an enormous care gap in the community and illustrates how much of a challenge it is for these parents to coordinate care for their children," Dr. Shah says. "We all work very well together to ensure that patients are appropriately diagnosed and receive treatment in a timely fashion."

**Dr. Manish Shah heads the Texas Comprehensive Spasticity Center, where a multidisciplinary approach ensures comprehensive treatment for each child.**

# A FRESH START *for* CRISTIAN SERRATO: DEEP BRAIN STIMULATION TRANSFORMS *a* LIFE

**M**uch of neurology is detective work. Like good sleuthing, successful practice demands profound knowledge, honed investigative skills, persistence and a measure of artistry. In the case of Cristian Serrato, diagnosis and treatment of a challenging disorder required all of these talents and more - the combined expertise of a multidisciplinary team of subspecialists affiliated with Children's Memorial Hermann Hospital, the Memorial Hermann Mischer Neuroscience Institute and McGovern Medical School at UTHealth.

---

**“DYSTONIA WAS THE BASELINE FROM WHICH CRISTIAN OPERATED. WHEN WE REMOVED IT, SHE WAS LEFT WITH WEAKNESS AND A LONG ROAD OF THERAPY AHEAD. BUT THE PSYCHOLOGICAL EFFECT OF THE SURGERY HAS BEEN REMARKABLE. AT HEART SHE IS A HAPPY TEENAGE GIRL AND IT HAS BEEN VERY REWARDING TO WATCH HER IMPROVE.”**

---

Born at term, Cristian was a small baby - just 4 pounds, 3 ounces. “From the beginning we had problems, but it was only later that they became serious,” says her mother, Lusi Serrato. “As a baby she never learned to roll over or sit up by herself, so we started home therapy very early. She was almost two when she learned to walk and she took longer than normal to reach her other milestones as well.”

Until the age of six, Cristian was walking, talking and eating normally. “Then one by one she started losing all the milestones she’d met,” says Guadalupe Serrato, her father. “I have videos of her going to the park, playing on the jungle gym, playing with her friends and then she could no longer do any of those things.”

When Cristian started school, she began to lose her voice, so her parents put her in speech therapy. “Then we noticed she wasn’t walking normally, so she started physical therapy,” her mother says. “And then she had problems with her hand movements, so we added occupational therapy.”

By the time Cristian was seven, she was in therapy sessions five days a week. “The more she grew, the worse the symptoms got,” Lusi Serrato says. “Eventually, she could no longer talk and we thought, ‘How do we communicate with her?’ We learned sign language and got her an iPad. She got very good at it.”



**PEDRO MANCIAS, M.D.**  
Professor, Department of Pediatrics,  
McGovern Medical School at UTHealth

In 2012, Cristian’s pediatrician referred her to Pedro Mancias, M.D., a pediatric neurologist whose clinical interests are neuromuscular disorders, electromyography and nerve conduction studies. “Cristian had a history of mild delays in speech and walking, and by the time I saw her she had experienced two years of regression in those abilities,” says Dr. Mancias, who is the Adriana Blood Professor of Pediatrics at McGovern Medical School. “She also had a known deletion in chromosome 19, but at the time it was discovered, its importance was unknown. We initiated a thorough evaluation including MRI, EMG, metabolic studies, lumbar puncture and a biopsy of muscle and conjunctiva. Cristian has been through a lot in her 13 years of life.”

The results of every test came back negative, but she continued to worsen to the point that her body had twisted into a contracted dystonic state. “We began researching the deletion in chromosome 19 and learned that it’s very close to the gene ATP 1A3, which is associated with two very rare conditions - alternating hemiplegia and rapid onset dystonia-parkinsonism,” Dr. Mancias





**Cristian Serrato's physician team recommended deep brain stimulation for a rare movement disorder. Now the teenager is making dramatic progress in outpatient rehabilitation.**

says. "Another patient we followed for many years presented with alternating hemiplegia. Eventually, through advances in genome sequencing, we discovered she had a deletion on ATP 1A3. Cristian presents with rapid onset dystonia-parkinsonism that we believe is associated with the chromosome 19 deletion, and we're investigating the genetics further. This is how one patient can help another, and hopefully will help other patients down the road."

The first goal in the treatment of movement disorders is always medical management, but Cristian had adverse effects that made increasing the prescription to effective doses impossible.

"With almost every follow-up visit to Dr. Mancias, we tried a new drug," Lusi Serrato says. "He talked to us about deep brain stimulation, but we were trying to avoid putting her through brain surgery. He described it in a way that wasn't so scary, but we thought this is our child and we'd be opening her brain. I said let's wait until it's the last resort. If I had known then what I know now, I wouldn't have put her through all those years of medications."

When a trial of levodopa-carbidopa failed to lead to improvement, Dr. Mancias involved his colleagues at UT MOVE, the Movement Disorders and Neurodegenerative Diseases Program at McGovern Medical School and Mischer Neuroscience Institute. In 2013, Cristian began seeing movement disorders specialist Erin Furr-Stimming, M.D., an associate professor at McGovern Medical

School, and her two fellows, Nivedita Thakur, M.D., who is now an assistant professor in the department of Pediatrics, and Allison Boyle, M.D., an assistant professor in the department of Neurology.

"UT MOVE got involved to determine whether there might be other more beneficial medications and to explore surgical interventions," Dr. Thakur says. "Cristian's disease was progressing and affecting all parts of her body. She couldn't sit in a chair. Her trunk was twisted, her left leg wouldn't straighten at all and her right leg was always turned when she walked. Her right hand was curled into a tight fist. What we saw was a child who was deteriorating rapidly with a dwindling quality of life. The most remarkable thing was that she was still a happy girl and very resilient."

Cristian was not a typical candidate for deep brain stimulation based on the literature. "As physicians we have to be safe and carefully consider the risk versus the benefit, but ultimately we have to be able to think outside the box," Dr. Thakur says. "Cristian simply had no other options. A multidisciplinary team came together to consider DBS for her - a bold move in a very rare condition - and made that recommendation to her parents."

In addition to Dr. Mancias, Dr. Furr-Stimming, Dr. Thakur and Dr. Boyle, Cristian's medical team included Manish Shah, M.D., who is director of the Texas



**ERIN FURR-STIMMING, M.D.**

Assistant Professor, Department of Neurology, McGovern Medical School at UTHealth



**NIVEDITA THAKUR, M.D.**

Assistant Professor, Department of Pediatrics, McGovern Medical School at UTHealth



**ALLISON BOYLE, M.D.**

Assistant Professor, Department of Neurology, McGovern Medical School at UTHealth



Comprehensive Spasticity Center and has expertise in the surgical management of pediatric spasticity and dystonia, and neurosurgeon Albert Fenoy, M.D., who specializes in deep brain stimulation, spinal cord stimulation and spasticity implantation surgery, as well as pain management and complex spine surgery.

The Serratos agreed to the surgery, which Dr. Fenoy and Dr. Shah performed in late October 2015 with Cristian under general anesthesia. Using MRI and intra-operative CT visualization, the surgical team made two burr holes in her skull and descended microelectrodes into the brain to verify neuronal activity and confirm that they had reached the target areas. Then they placed the DBS leads, test stimulated to check her response, placed extensions from the electrodes to the neurostimulator and implanted it in her chest under the clavicle.

After the surgery Dr. Thakur and Dr. Boyle worked together to program the neurostimulator, and they continue to fine-tune the settings. “We follow Cristian closely in clinic once a month,” Dr. Thakur says. “Dystonia was the baseline from which she operated. When we removed it, she was left with weakness and a long road of therapy ahead. But the psychological effect of the surgery has been remarkable. At heart Cristian is a happy teenage girl and it has been very rewarding to watch her improve.”

Cristian started therapy at TIRR Memorial Hermann Outpatient Rehabilitation-Kirby Glen in January. Occupational therapist Carly Thom, OTR, works with her two days a week.

“Now that Cristian can open her hands, we’re working on relearning how to use them,” Thom says. “She’s very motivated and excited about everything new we do. She can’t communicate verbally, but that doesn’t stop her from communicating. She’s a unique child.”

As a sixth-grader at Deep Water Junior High School in Deer Park, Texas, Cristian keeps a full morning-to-afternoon schedule. “She uses a wheelchair to get from

one place to the next, but when we get there, she usually prefers to sit in a regular chair,” her father says. “Now that she’s beginning to be able to swallow, she has strong preferences in food – macaroni, hot dog mustard only, hamburger mustard only, pizza, no broccoli.”

Cristian’s ability to walk improved after the surgery. “We both have to tell her to slow down because she’s always in a hurry,” Guadalupe Serrato says. “She remembers what she could do when she was six and wants to have it all back. She’s very social and interacts well with other kids and adults. She laughs. She listens. She’s a normal teenage girl trapped inside her body.”

The Serratos had researched rapid onset dystonia-parkinsonism online and found very little information. “Some of these conditions have been studied more

in adults than in children, which is the advantage of being treated at a children’s hospital housed within an adult hospital, both of which are teaching hospitals for a medical school,” Dr. Thakur says. “We all work together as a team, but at the same time we maintain our independent thinking processes. That kind of close teamwork is based on the long-term experience of working together and it gives our patients more confidence in treatment decisions.”

Meanwhile, the Serratos are watching their daughter come out of her shell. “She’s always ready to try new things,” Lusi Serrato says. “She likes everyone she meets and greets them with a smile. Here is my daughter, trapped inside this body, and she’s amazing! She inspires me every day. We’ve seen what this surgery has done for Cristian and want others to hear her story.”

## Using Sophisticated Brain-imaging Techniques to Help Make the Treatment Decision for Patients with Spastic Cerebral Palsy

To advance the standard of care for children with spastic cerebral palsy, researchers at Children’s Memorial Hermann Hospital and McGovern Medical School are developing sophisticated brain-imaging techniques to complement clinical judgment in treatment decision-making.

“Cerebral palsy (CP) remains one of the most common neurological complications of birth, affecting about one in 500 infants,” says Manish N. Shah, M.D., who directs the Texas Comprehensive Spasticity Center at McGovern Medical School, Children’s Memorial Hermann Hospital and the Memorial Hermann Mischer Neuroscience Institute at the Texas Medical Center. “The most common form of CP is spastic cerebral palsy associated with prematurity and intraventricular hemorrhage. The hemorrhage causes periventricular leukomalacia, which results in an axonal injury that can be seen on diffusion tractography MRI. The end result of the axonal injury is rigidity and spasticity.”

Sectioning 75 to 80 percent of the dorsal roots by selective dorsal rhizotomy (SDR) has been shown to permanently eliminate spasticity in patients with spastic diplegia. “With intensive physical therapy, patients who have had the specific surgery we perform at Children’s Memorial Hermann Hospital can learn to walk, which vastly improves their quality of life,” says Dr. Shah, an assistant professor in the division of Pediatric Neurosurgery and director of pediatric spasticity and movement disorder surgery at McGovern Medical School. “We have solid clinical criteria that define the optimal SDR candidate, but there are no imaging metrics to help us determine the best candidates for surgery and provide feedback on the effectiveness of physical therapy after surgery.”

Dr. Shah and his team believe that the next step in advancing treatment is to identify the imaging paradigms that best delineate the course of patients with spastic diplegia before and after SDR. “By doing so, we’ll be better able to classify patients and intervene early on, before spasticity causes damage to muscles and joints that leads to orthopedic deformities and more surgeries down the road to correct them,” he says. “Imaging studies that provide in-depth information particular to each patient will also allow us to design postoperative physical therapy specific to the patient, and will illuminate us about long-term changes in cortical plasticity that result from the surgery.”

# TOWARD *a* NEW PARADIGM for the TREATMENT of INTRACTABLE EPILEPSY

**C**an MEG-based analysis of the epileptic network in children improve the way physicians treat intractable epilepsy? Physician researchers affiliated with Children’s Memorial Hermann Hospital and the Mischer Neuroscience Institute at Memorial Hermann-Texas Medical Center are among a small group of specialists worldwide who believe that the future of epilepsy treatment lies in the study of brain networks using magnetoencephalography. Their aim is to use MEG-guided computational network analysis for evaluation and surgical planning, with the ultimate goal of making epilepsy surgery an option for more children – and eventually leading to the development of new surgical approaches.



**GRETCHEN VON ALLMEN, M.D.**  
Associate Professor, Chief of Pediatric Epilepsy, Director of the Pediatric Epilepsy Program, Department of Pediatrics, McGovern Medical School

“MEG allows us to create a dynamic model of the epileptic network that can be manipulated in a search for ways to disable the network in children with intractable epilepsy,” says Gretchen Von Allmen, M.D., chief of pediatric epilepsy at Children’s Memorial Hermann Hospital, director of the Pediatric Epilepsy Program at McGovern Medical School at UTHealth and an associate professor in the department of Pediatrics. “It also will allow us to test the predictive accuracy of the MEG model against actual surgical results. Eventually, new surgical and nonsurgical methods can be

explored, including less invasive techniques that will disable the network while preserving brain tissue.”

The issue is relevant. Approximately 2.2 million people in the United States have epilepsy, and 150,000 new cases are diagnosed each year. One in 26 people will develop epilepsy in his or her lifetime, with the highest incidence in children younger than age 15 and adults over the age of 65. One-third of children with epilepsy do not respond to anticonvulsant medication taken on a daily basis to prevent seizures.

“The goal of epilepsy treatment is to control seizures as quickly as possible to optimize cognitive development and improve quality of life,” Dr. Von Allmen says. “Once a child fails two or three different anti-seizure medications with the proper drug and dosing, the chance of becoming seizure free with subsequent drugs is less than 2 percent. These children are placed into the intractable category. Persistent seizures, especially in early childhood, have a detrimental effect on cognitive and social development and on quality of life. The longer a child continues to have seizures, the greater the damage to the brain.”

Children’s Memorial Hermann Hospital and Mischer Neuroscience Institute are pioneering sites for robotic stereoelectroencephalography (SEEG), a technique that helps to localize the seizure focus with precision in a minimally invasive fashion. The Institute was the second site in the nation where affiliated physicians used the technique, and they have managed more than 75 patients in the past two

years, with zero morbidity and a high success rate in localizing seizures.

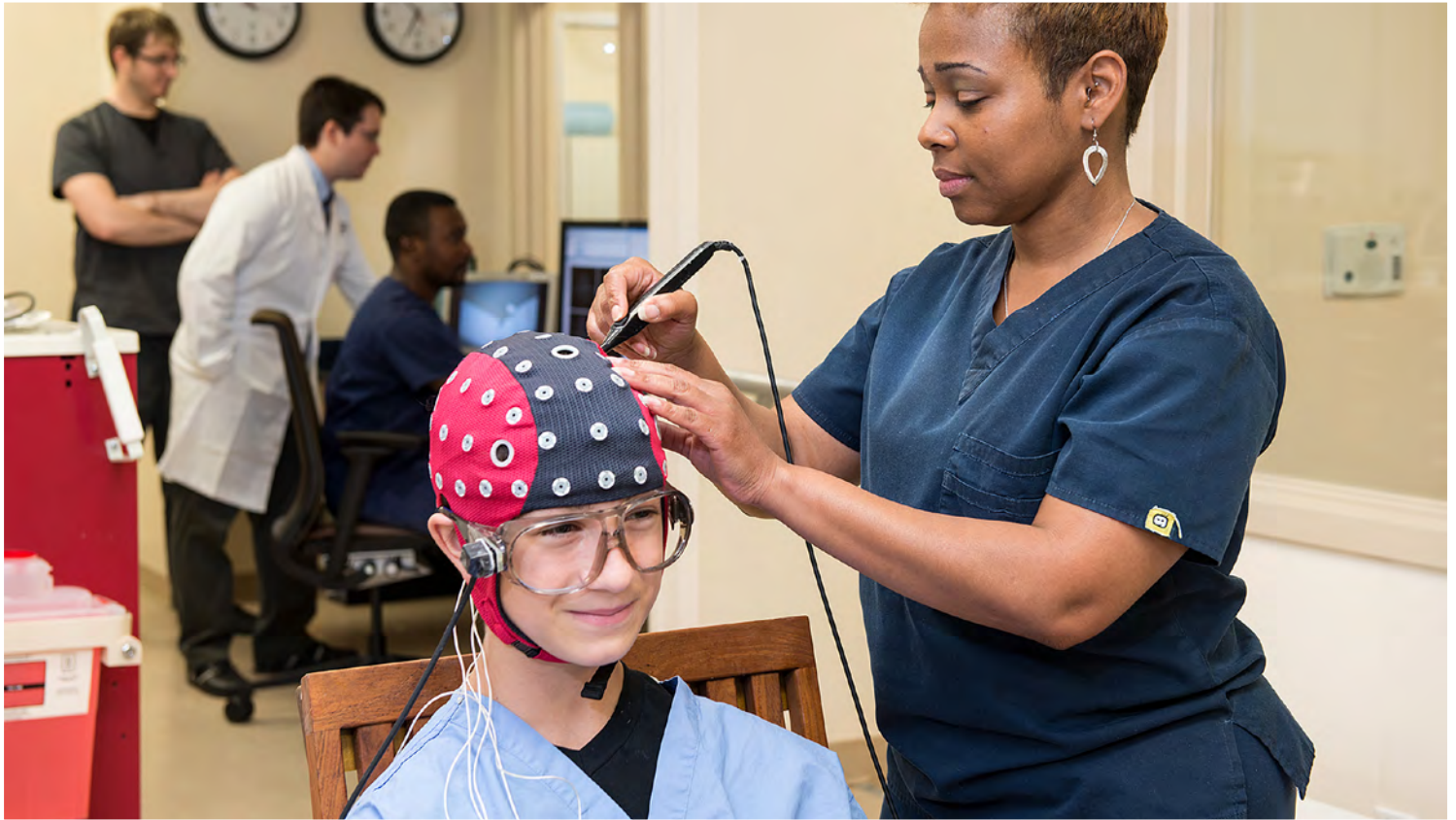“Surgery is a very effective treatment in cases of focal epilepsy, but the average length of time from seizure onset to surgery is 17 to 23 years,” says MEG expert Michael Funke, M.D., Ph.D., medical director of Memorial Hermann Magnetic Source Imaging and an associate professor in the division of Child and Adolescent Neurology in the department of Pediatrics at McGovern Medical School. “No one test alone can determine the area of the brain generating the child’s seizures, so we use many noninvasive pre-surgical tools to localize seizures, including brain imaging with 3 Tesla MRI, PET, SPECT, fMRI and diffusion tensor imaging, a promising method for characterizing microstructural changes in neuropathology before and after treatment. We also use neurophysiological testing of brain function in real time using EEG and MEG. This technology is excellent, but we believe the first step in advancing epilepsy treatment is to look beyond the focal point and better define brain networks in children who don’t respond to medication.”



**MICHAEL FUNKE, M.D., Ph.D.**  
Associate Professor, Director of MEG, Department of Pediatrics, McGovern Medical School at UTHealth

Dr. Funke and Dr. Von Allmen are among a handful of researchers around the world engaged in the investigation of the use of MEG to map brain networks before and after treatment for epilepsy. “Some research groups are using fMRI in an attempt to identify abnormal epileptic networks, but MEG has several advantages,” Dr. Funke says. “MEG is the only modality that provides real-time neurophysiological data, without the limitations of EEG. The procedure is completely noninvasive with a very short test duration, which makes it appropriate for patients of all ages, including babies. While MEG is currently used to localize sources of epileptiform activity in





preparation for epilepsy surgery, it can also be used to analyze brain function networks during epileptic seizures.”

Dr. Funke brings to the table 22 years of experience working with MEG and a wealth of connections in the international community of researchers using the neuroimaging technique for research on brain networks. He and Dr. Von Allmen are currently collaborating with researchers in Spain: Fernando Maestú and Ricardo Bajo at the Laboratory of Cognitive and Computational Neuroscience at Complutense University of Madrid; and Pablo Cuesta, Ph.D., a neuroscientist at the Universidad Politécnica de Madrid.

“Based on their record of publication and grant funding, they are among the best groups in the field,” Dr. Von Allmen says. “In addition to global collaboration, we have an excellent team that makes full use of the interplay between clinical care and research. Because I see patients, I bring up clinical questions that people focused solely on research might not consider. These interactions between clinical care and basic science are important in moving our discipline forward through discovery.

Dr. Funke is a bridge between the two worlds, which leads to new ideas. So the question at hand is if resective surgery is the best and only approach to intractable epilepsy. There have been no significant changes in seizure freedom rates post surgery for more than 20 years, despite significant advances in pre-surgical tools to localize the epileptogenic zone and in surgical techniques. Today, there is much more evidence to suggest that epilepsy and the brain in general are network based, rather than focus based. We believe a new approach is required that can identify the epileptic network generating the seizures. From there, we can search for new ways to stop the epileptic activity and spare the brain’s normal functional networks.”

The research teams in Houston and Madrid are in the process of gathering preliminary data that will pave the way for an application for federal funding to pursue the use of MEG to identify epileptic networks. They are also developing a pilot study to test a novel approach to predict the efficacy of vagal nerve stimulation (VNS) in pediatric patients with intractable epilepsy. “Currently, there are

**Dr. Michael Funke and Dr. Gretchen Von Allmen are among a handful of researchers using MEG to map brain networks before and after epilepsy treatment. Here, a patient is fitted with an EEG cap prior to testing.**

no biomarkers that predict the response to VNS therapy in patients with intractable epilepsy,” Dr. Von Allmen says. “Based on outcome definition, there are up to 60 percent of positive responders in this patient population, but a much lower number for seizure freedom. We hope to improve those statistics through our study of epileptic networks before and after the therapy.”

The brain is dynamic, with a multitude of systems working together depending on the task at hand. “With technology like MEG that records data from the brain in very high resolution, we can use mathematical algorithms to discover where the connections lie and which areas of the brain are driving the activity in particular situations,” Dr. Funke says. “The functional connectivity of networks is a relatively new topic for research. We are all learning as we go.”

# METHOTREXATE INFUSION DIRECTLY *into the* FOURTH VENTRICLE *in* CHILDREN *with* MALIGNANT FOURTH VENTRICULAR BRAIN TUMORS

**T**ranslational studies conducted by David I. Sandberg, M.D., FAANS, FACS, FAAP, have demonstrated the safety of infusing chemotherapeutic agents directly into the fourth ventricle to treat children with recurrent malignant tumors in this location in the brain. The results of these studies led to a pilot clinical trial completed

**“THIS RADICALLY NEW APPROACH TO CHEMOTHERAPY ALLOWS US TO CIRCUMVENT THE BLOOD-BRAIN BARRIER AND DELIVER AGENTS DIRECTLY TO THE SITE OF DISEASE WHILE MINIMIZING SIDE EFFECTS BY DECREASING SYSTEMIC DRUG EXPOSURE.”**

in August 2015 and a new methotrexate dose-escalation study available only at Children’s Memorial Hermann Hospital in collaboration with the Memorial Hermann Mischer Neuroscience Institute at the Texas Medical Center.



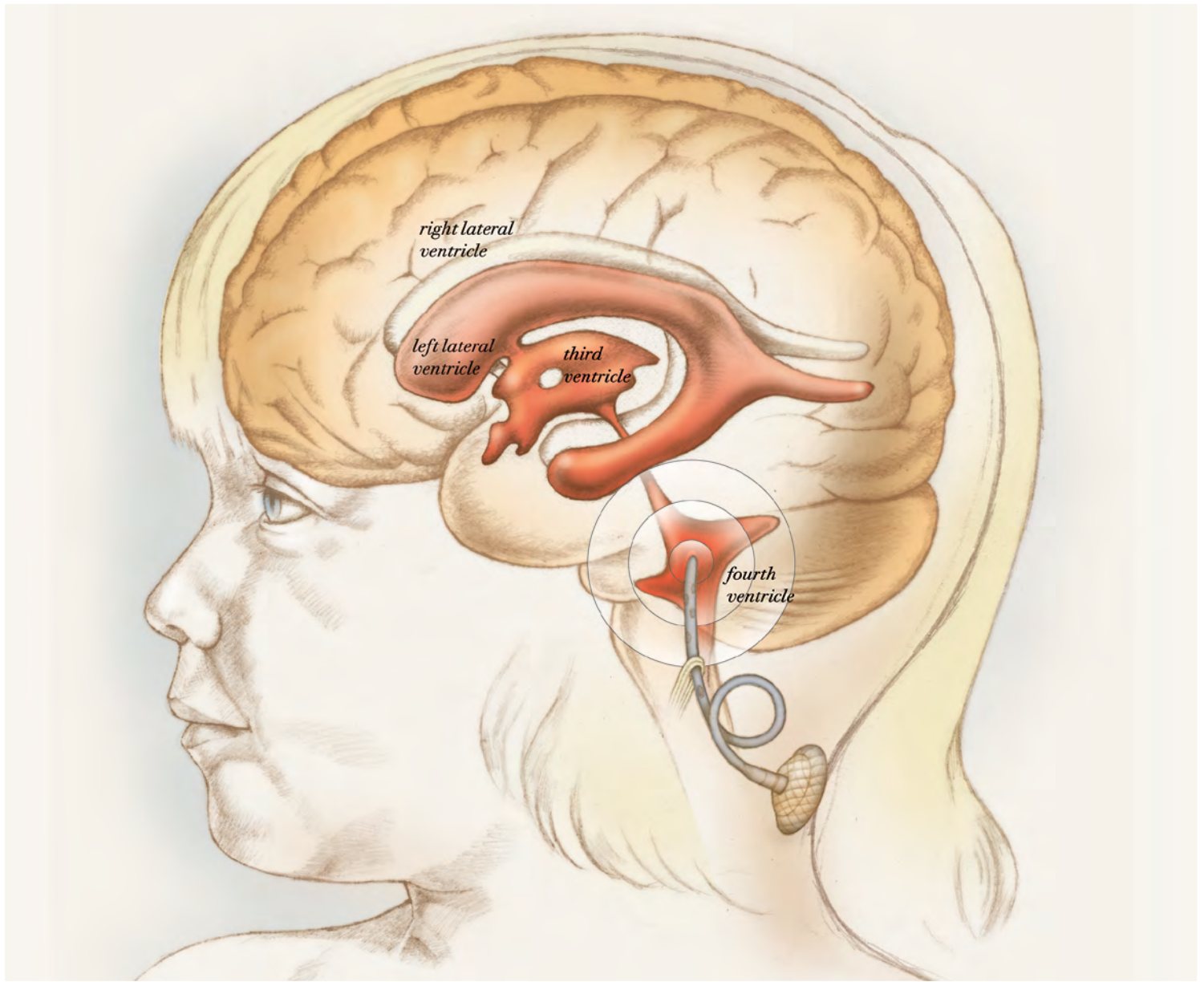
**DAVID I. SANDBERG, M.D., FAANS, FACS, FAAP**  
Director, Pediatric Neurosurgery, Mischer Neuroscience Institute; Associate Professor, Department of Pediatric Surgery and Vivian L. Smith Department of Neurosurgery; Dr. Mamie Rose Professorship in Pediatric Neurosurgery at McGovern Medical School at UTHealth

“This radically new approach to chemotherapy allows us to circumvent the blood-brain barrier and deliver agents directly to the tumor site to decrease systemic drug exposure and minimize side effects,” says Dr. Sandberg, who is director of pediatric neurosurgery at Children’s Memorial Hermann Hospital and Mischer Neuroscience Institute. “Now that we’ve determined that methotrexate can be infused into the fourth ventricle without causing neurological toxicity, and that some patients with recurrent medulloblastoma experience a beneficial anti-tumor effect both within the fourth ventricle and at distant sites, we’ve taken the study a step further to determine the optimum dose of the agent.”



**Dr. David Sandberg’s innovative clinical trial offers new hope for children with malignant tumors located in the fourth ventricle.**





The pilot clinical trial was conducted at Children’s Memorial Hermann Hospital and The University of Texas MD Anderson Cancer Center, where Dr. Sandberg is co-director of the Pediatric Brain Tumor Program. Five patients - three with medulloblastoma and two with ependymoma - received 18, 18, 12, 9 and 3 cycles of chemotherapy, respectively, through a catheter surgically placed into the fourth ventricle and attached to a ventricular access device. No serious adverse events or new neurological deficits were attributed to treatment with methotrexate. The results were published in the *Journal of Neuro-Oncology* in 2015.<sup>1</sup>

The new dose-escalation study will enroll a minimum of 12 patients at

Children’s Memorial Hermann Hospital. To date, three patients have participated in the clinical trial, the only such study under way in the world.

“Despite advances in pediatric oncology, we’re still seeing too many children die of malignant brain tumors, and the treatments currently available are not satisfactory for children,” says Dr. Sandberg, an associate professor with joint appointments in the department of Pediatric Surgery and the Vivian L. Smith Department of Neurosurgery at McGovern Medical School. “Many suffer extreme toxicity from chemotherapy and radiation, and I believe we can do better. I hope to improve on what we can currently offer as treatment - with fewer complications.”

**Chemotherapy is delivered directly into the brain via a catheter surgically placed into the fourth ventricle and attached to a ventricular access device.**

<sup>1</sup> Sandberg DI, Rytting M, Zaky W, Kerr M, Ketonen L, Kundu U, Moore BD, Yang G, Hou P, Sitton C, Cooper LJ, Gopalakrishnan V, Lee DA, Thall PF, Khatua S. Methotrexate administration directly into the fourth ventricle in children with malignant fourth ventricular brain tumors: a pilot clinical trial. *Journal of Neuro-Oncology*. 2015 Oct;125(1):133-41. doi: 10.1007/s11060-015-1878-y. Epub 2015 Aug.

# RILEY LENTZ: NO STONE UNTURNED

**F**ifteen-year-old Riley Lentz is no stranger to hospitals. Diagnosed with malignant medulloblastoma in 2008, she underwent two open brain surgeries to remove the tumor and later, two noninvasive radiosurgical CyberKnife® procedures. When the tumor recurred in 2013, she was given high-dose chemotherapy and received a stem cell transplant to help her body bounce back after the infusions.

“After the chemo, we went until April or May of 2015 before they found another small spot and opted to try the CyberKnife for the second time,” says Riley’s mother, Melissa Saban. “At her three-month follow-up MRI, we learned that the procedure didn’t help.”

**“AFTER RILEY’S ONCOLOGIST TOLD US HER BODY WOULDN’T TOLERATE ANY MORE SYSTEMIC CHEMO, I STARTED LOOKING FOR OTHER OPTIONS. I WAS FORTUNATE TO FIND ANOTHER PARENT ON THE FACEBOOK PAGE WHOSE CHILD HAD JUST FINISHED THE CLINICAL TRIAL IN HOUSTON.”**

Somewhere along the way, Saban joined a Facebook group called Parents of Kids with Medulloblastoma, a forum for parents who want to share their knowledge and experience. “I had heard about a clinical trial of direct infusion of chemotherapy into the fourth ventricle around the time Riley had the stem cell transplant in 2013,” she says. “After her oncologist told us her body wouldn’t tolerate any more systemic chemo, I started looking for other options. I was fortunate to find another parent on the Facebook page whose child had just finished the clinical trial in Houston.”

Through Parents of Kids with Medulloblastoma, Saban connected with Marcia Kerr, RN, CCRC, research coordinator for pediatric neuroscience at McGovern Medical School at UTHHealth.

Among the trials Kerr coordinates is one led by David I. Sandberg, M.D., FAANS, FACS, FAAP, director of pediatric neurosurgery at Children’s Memorial Hermann Hospital, the Memorial Hermann Mischer Neuroscience Institute at the Texas Medical Center and McGovern Medical School.

Before his arrival in Houston in 2012, Dr. Sandberg conducted translational studies that demonstrated the safety of infusing chemotherapeutic agents directly into the fourth ventricle to treat children with recurrent malignant brain tumors in this location. The promising results of those studies led to a pilot clinical trial completed in August 2015 and a new methotrexate dose-escalation study

available only at Children’s Memorial Hermann Hospital in collaboration with Mischer Neuroscience Institute.

“Delivering chemotherapeutic agents directly to the site of disease minimizes the side effects for children like Riley by decreasing systemic drug exposure,” says Dr. Sandberg, an associate professor with dual appointments in the Vivian L. Smith Department of Neurosurgery and the Department of Pediatric Surgery at McGovern Medical School. “After we determined that methotrexate can be infused into the fourth ventricle without causing neurological toxicity, and that some patients with recurrent medulloblastoma experience a beneficial anti-tumor effect both within the fourth ventricle and at distant sites, our next step



**MARCIA KERR, RN, CCRC**

*Clinical Trial Program Manager, Department of Pediatric Surgery, McGovern Medical School at UTHHealth*



**DAVID I. SANDBERG, M.D., FAANS, FACS, FAAP**

*Director, Pediatric Neurosurgery, Mischer Neuroscience Institute; Associate Professor, Department of Pediatric Surgery and Vivian L. Smith Department of Neurosurgery; Dr. Mamie Rose Professorship in Pediatric Neurosurgery at McGovern Medical School at UTHHealth*

was a dose-escalation study to determine the optimum dose of the agent.”

Riley was among the first participants enrolled in the clinical trial at Children’s Memorial Hermann Hospital, the only such study under way in the world. In a surgery that took place on Nov. 3, 2015, Dr. Sandberg removed as much of the tumor as possible and placed a reservoir for the direct delivery of chemotherapy – a catheter and plastic disk covered by a rubber balloon underneath the skin at the back of Riley’s neck.

Riley and other children who participate in the trial undergo three cycles of chemotherapy and an MRI before and after treatment. Each cycle includes an infusion on Monday and Thursday for three weeks, followed by a rest week.

Over the next three months, Saban and her former husband, Jeff Lentz, made the 16-hour round trip twice a week from their home in Greenbriar, Arkansas, to Houston. “Riley’s dad didn’t want me to make the trip alone,” she says. “Both of us have remarried and have other kids, which made it difficult to find childcare that would allow us to stay in Houston during Riley’s treatment. So we chose to drive down and back the same day.”

On January 29, 2016, just before Riley completed the clinical trial, Saban posted an update on her Facebook page. “The treatment is working – the plan is to continue the same treatment and then start another round at Arkansas Children’s Hospital. We are beyond excited!!!!”

“Once we’ve shown that the treatment is safe and the child is responding to it,





**Riley Lentz was among the first participants in a new study to determine the optimum dose of methotrexate delivered directly to the fourth ventricle of the brain.**

we're happy if we can find a pediatric oncologist to continue it," Dr. Sandberg says. "Riley came to us from Arkansas and had a dramatic response. Her parents are unbelievably dedicated, leaving no stone unturned to help their daughter, including making the 16-hour round-trip drive to Houston twice a week. They're good people, and Riley is the sweetest kid. We're thrilled to get this kind of positive response to the treatment without the toxicity of systemic chemotherapy, and we're grateful to Riley's oncologist for continuing the treatment in Little Rock."

Saban describes the family's experience in Houston as very positive. "I loved Dr.

Sandberg," she says. "He's personable and caring and extremely passionate about what he's doing to help kids. And he was great with Riley."

As for Riley, she takes it all in her stride. "We've been fighting cancer for so long that it's become a part of her daily life," Saban says. "We've always been honest with her and we always listen to what she tells us. She's never said, 'Okay, I'm done with this.' She takes it with a grain of salt and is doing amazingly well considering how much she's been through and how different her life is from the lives of other kids."

---

FOR MORE INFORMATION ABOUT THE CLINICAL TRIAL, VISIT [CHILDRENS.MEMORIALHERMANN.ORG/ PEDIATRIC-BRAIN-TUMOR-TRIAL](http://CHILDRENS.MEMORIALHERMANN.ORG/ PEDIATRIC-BRAIN-TUMOR-TRIAL) OR CONTACT MARCIA KERR AT 713.500.7363 OR VIA EMAIL AT [MARCIA.L.KERR@UTH.TMC.EDU](mailto:MARCIA.L.KERR@UTH.TMC.EDU).

## Detecting Pediatric Brain Tumors

Pediatric brain tumors are the second most common cancer in children, with approximately 2,500 to 3,500 brain tumors diagnosed in the United States each year. Brain tumors in children are different from those in adults in cell type, presentation and responsiveness to treatment.

"Because the brain is still developing, it's important for children and adolescents to be diagnosed and treated by a physician team that specializes in pediatric brain tumors," says David I. Sandberg, M.D., FAANS, FACS, FAAP, director of pediatric neurosurgery at Children's Memorial Hermann Hospital and Mischer Neuroscience Institute and co-director of the Pediatric Brain Tumor Program at The University of Texas MD Anderson Cancer Center. "Tumors present in a variety of ways depending on their location in the brain. The most common signs and symptoms are headache and vomiting due to elevated intracranial pressure. In infants and young children, irritability or a fontanelle that is fuller than normal may signal elevated intracranial pressure."

Other signs and symptoms include motor weakness, sensory changes, personality changes, unsteady gait, difficulty with muscle control, lethargy, seizures, vision changes, speech problems and endocrine disorders.

The Pediatric Brain Tumor Program brings together a team of experts affiliated with Children's Memorial Hermann Hospital and The University of Texas MD Anderson Children's Cancer Hospital to serve physicians, patients and families with new and advanced methods of diagnosing and treating childhood brain tumors. The program team includes board-certified specialists in neuro-oncology, pediatric neurosurgery, radiation oncology, neuroradiology, neuropathology, neuropsychology and survivorship. Additional support is provided by psychologists, nutritionists, social workers and Child Life specialists, as well as developmental and education specialists.

For more information about the Pediatric Brain Tumor Program, please contact the division of Pediatric Neurosurgery at McGovern Medical School at **832.325.7242** or visit [childrens.memorialhermann.org/pbtp](http://childrens.memorialhermann.org/pbtp).

# CLINICAL TRIALS *for* RARE DISORDERS

## Early Biomarkers of Autism Spectrum Disorder in Infants with Tuberous Sclerosis Complex

Investigators at Children's Memorial Hermann Hospital and McGovern Medical School are enrolling three-month-old to 12-month-old infants with a diagnosis of tuberous sclerosis complex (TSC) in an innovative study to identify early markers of autism. Children's Memorial Hermann Hospital is the only institution in Houston participating in the five-year multicenter study.

With funding from the National Institute of Neurological Disorders and Stroke, the researchers are using behavioral testing, MRI imaging and electroencephalography techniques to identify children at risk for developing autism starting at three months of age and continuing until 36 months of age.

Autism spectrum disorder is common in the population of children with TSC with about 50 percent of such patients affected. To characterize the development

of infants with TSC, study participants will be evaluated longitudinally at ages 3, 6, 9, 12, 18, 24 and 36 months. At each age, the children will undergo standardized evaluation using cognitive and adaptive measures. At ages 24 and 36 months, the researchers will perform a formal assessment for autism. Clinical data, including medication use, seizure history, EEG activity, genotypic variation and co-morbidities, will be recorded to determine if specific clinical factors are modifying the course of development.

The diagnosis of TSC is based on established clinical criteria and will not require genetic testing prior to enrollment. Throughout the study, the investigators will recommend early intervention services for any child who shows signs of autism.

Principal investigator at the Houston site is Hope Northrup, M.D., professor of pediatrics and director of the division of Medical Genetics at McGovern Medical School. Dr. Northrup is director of the Tuberous Sclerosis Center of Excellence



**HOPE NORTHRUP, M.D.**

Professor, Director of Division of Medical Genetics, Department of Pediatrics, McGovern Medical School at UTHealth

at Children's Memorial Hermann Hospital, one of only five TSC Centers nationwide participating in the study.

TO LEARN MORE ABOUT THE STUDY, CONTACT ELIDA SALAZAR AT [ELIDA.L.SALAZAR@UTH.TMC.EDU](mailto:ELIDA.L.SALAZAR@UTH.TMC.EDU) OR 713.500.5766.

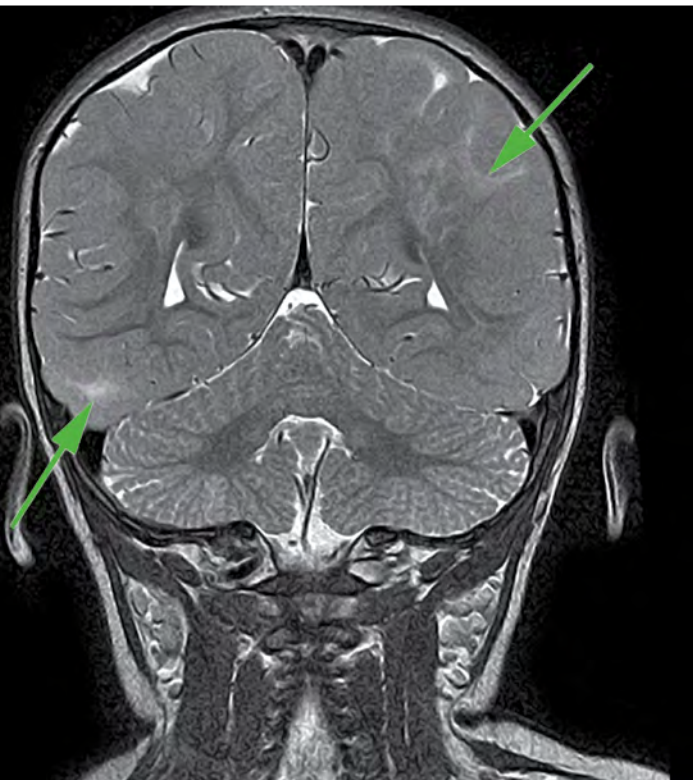
## Continuation Study for Individuals Diagnosed with Autism Spectrum Disorders and Tuberous Sclerosis Complex

Researchers at Children's Memorial Hermann Hospital and four other institutions across the country are working to learn more about the developmental phenotype of autism spectrum disorder (ASD) and intellectual disability (ID) in children with tuberous sclerosis complex (TSC). Participants in the Early Biomarkers of Autism Spectrum Disorders trial may enroll in this clinical research continuation study for children and adolescents ages three to 21 who have a diagnosis of TSC and ASD and/or ID.

The goal of the multicenter study, conducted as part of the Rare Disease Clinical Research Network and sponsored by the National Institutes of Health, is to gain a better understanding of autism spectrum disorder and intellectual disability that will lead to the development of effective treatments and interventions.

Participation in the study involves five visits over a two-year period. Three of the visits will occur at Children's Memorial Hermann Hospital and involve a blood draw, physical and neurological exams and development testing. Two visits will occur as phone calls and involve

Coronal T2 image demonstrates multiple bilateral cortical tubers (arrows).





answering questionnaires about behavior and development.

Principal investigator at the Houston site is Hope Northrup, M.D., professor of pediatrics, director of the division of Medical Genetics at McGovern Medical School and director of the Tuberous Sclerosis Center of Excellence at Children's Memorial Hermann Hospital, one of only five TSC Centers nationwide participating in the study.

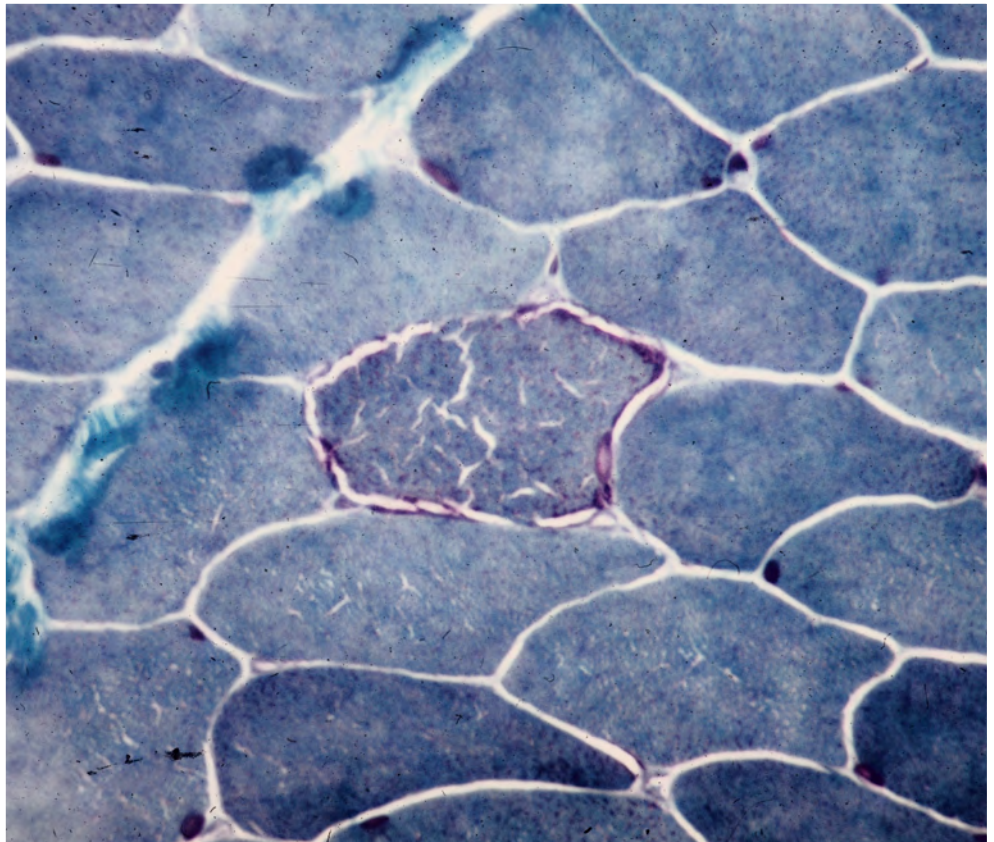
TO LEARN MORE ABOUT THE STUDY, CONTACT ELIDA SALAZAR AT [ELIDA.L.SALAZAR@UTH.TMC.EDU](mailto:ELIDA.L.SALAZAR@UTH.TMC.EDU) OR 713.500.5766.

### Intra Erythrocyte Dexamethasone in the Treatment of Ataxia Telangiectasia

Children's Memorial Hermann Hospital is one of four hospitals in the United States selected as a site for the international multicenter phase III clinical trial of a novel experimental combination product for the treatment of ataxia telangiectasia (AT). A rare, progressively disabling and life-shortening genetic disease for which no therapy is currently available, AT is characterized by severe progressive neurodegeneration from early infancy. Specific features include progressive ataxia of the trunk and limbs, involuntary movements, oculomotor apraxia, difficulties in speech and swallowing and delayed peripheral neuropathy.

The study, if successful, could constitute the basis for FDA approval of EryDel's experimental combination product EryDex System (EDS). EDS delivers dexamethasone sodium phosphate by encapsulating the drug into red cells taken from the patient's own blood, which are then immediately infused into the patient. EryDel recently completed a pilot phase II trial in AT patients that demonstrated the statistically significant efficacy of EDS on both primary and secondary outcome measures.

The phase III trial will be a randomized, prospective, double-blind, placebo-controlled study designed to



**This trichrome stain of a muscle biopsy shows degeneration of the fiber inside the red ring.**

assess the effect of two dose ranges of EDS on neurological symptoms of AT patients. Under a European Horizon 2020 program, an international patient registry will also be set up, with the aim of establishing and maintaining a comprehensive clinical database of patients with AT and closely related conditions. The registry will enable the monitoring of AT epidemiology, the development of an evidence-based natural history of the condition, identification of biomarkers and development of clinical guidelines.

Principal investigator for the trial at Children's Memorial Hermann Hospital, expected to begin in summer 2016, is Mary Kay Koenig, M.D., associate professor, director of the Mitochondrial Center of Excellence, co-director of the Tuberous Sclerosis Center of Excellence and Endowed Chair of Mitochondrial Medicine. Co-investigators are Nivedita Thakur, M.D., an assistant professor in the department of Pediatrics at McGovern Medical School, and John M. Slopis, M.D., professor and medical director of the Neurofibromatosis Program in the department of Neuro-oncology at The University



**MARY KAY KOENIG, M.D.**  
*Associate Professor & Director, Mitochondrial Center of Excellence; Co-director, Tuberous Sclerosis Center of Excellence, Department of Pediatrics, McGovern Medical School at UTHealth*



**NIVEDITA THAKUR, M.D.**  
*Assistant Professor, Department of Pediatrics, McGovern Medical School at UTHealth*



**JOHN M. SLOPIS, M.D.**  
*Professor, Department of Pediatrics, McGovern Medical School at UTHealth*

of Texas MD Anderson Cancer Center, who holds a joint appointment as professor in the department of Pediatrics at McGovern Medical School. The researchers' long-term goal is to develop a center in Houston for patients with ataxia telangiectasia.

TO LEARN MORE ABOUT THE STUDY, EMAIL [ATAXIA@UTH.TMC.EDU](mailto:ATAXIA@UTH.TMC.EDU).

# NEWS of NOTE

## Children's Memorial Hermann Hospital and McGovern Medical School Welcome Pediatric Neurologist



**MICHAEL W. WATKINS, M.D.**

Assistant Professor, Department of Pediatrics, McGovern Medical School at UTHealth

Michael W. Watkins, M.D., has joined the faculty of McGovern Medical School and the medical staff of Children's Memorial Hermann Hospital and the Memorial Hermann Mischer Neuroscience Institute at the Texas Medical Center. Dr. Watkins focuses his practice on the evaluation and treatment of epilepsy in children, particularly intractable epilepsy, including the use of magnetoencephalography (MEG) in the evaluation of pediatric patients with medically refractory seizures.

An assistant professor in the department of Pediatrics, division of Child Neurology, Dr. Watkins received his medical degree at McGovern Medical School at UTHealth and completed residencies in general pediatrics and pediatric neurology at the same institution. He was chief pediatric neurology resident in 2012 and was awarded the UTHealth Child and Adolescent Neurology Resident Excellence in Teaching Award in 2013.

Following residency, Dr. Watkins completed fellowships in clinical neurophysiology and in clinical magnetoencephalography and neurosurgical epilepsy at McGovern Medical School. His research interests include surgical outcomes following epilepsy surgery, as well as the use of MEG in the evaluation of epileptic networks in patients with intractable epilepsy and West syndrome.

Dr. Watkins is a member of the American Epilepsy Society, American Clinical MEG Society, Child Neurological Society, American Academy of Pediatrics and American Academy of Neurology.

## Dr. David Sandberg Awarded the Inaugural Dr. Marnie Rose Professorship in Pediatric Neurosurgery



**DAVID I. SANDBERG, M.D., FAANS, FACS, FAAP**

Director, Pediatric Neurosurgery, Mischer Neuroscience Institute; Associate Professor, Department of Pediatric Surgery and Vivian L. Smith Department of Neurosurgery; Dr. Marnie Rose Professorship in Pediatric Neurosurgery at McGovern Medical School at UTHealth

Pediatric neurosurgeon David I. Sandberg, M.D., FAANS, FACS, FAAP, is the inaugural recipient of the Dr. Marnie Rose Professorship in Pediatric Neurosurgery at UTHealth's McGovern Medical School. Dr. Sandberg is director of pediatric neurosurgery at Children's Memorial Hermann Hospital, the Memorial Hermann Mischer Neuroscience Institute at the Texas Medical Center and McGovern Medical School, where he holds joint faculty appointments in the department of Pediatric Surgery and the Vivian L. Smith Department of Neurosurgery.

The professorship is funded by a gift from the Dr. Marnie Rose Foundation, established by Lanie and Jerry Rose in memory of their daughter. The foundation was created to raise funds in support of brain cancer research and other special projects benefiting children.

A 2000 graduate of McGovern Medical School, Dr. Rose was diagnosed with a rare type of brain cancer in the first year of her pediatric medical residency at Children's Memorial Hermann Hospital, the medical school's pediatric teaching hospital. In 2002, she agreed to share her cancer journey, personal life and professional responsibilities as a medical resident with a TV crew from the ABC reality series *Houston Medical*. The critically acclaimed hospital series followed the lives of doctors, nurses and other healthcare professionals and patients

**Pediatric neurosurgeon Dr. David Sandberg (center) with Lanie and Jerry Rose, who established the Dr. Marnie Rose Foundation in memory of their daughter.**





at Memorial Hermann-Texas Medical Center and aired nationally on ABC for six weeks in the summer of 2002.

In the show's debut episode, Dr. Rose stunned viewers by pulling off her wig, revealing that she was both a doctor and a patient. Viewers were inspired by her determination to keep working despite her illness, her candor about her disease and her positive attitude in the face of adversity. Dr. Rose died in August 2002, a few weeks after the final episode of *Houston Medical* aired.

"We are proud to honor Marnie's legacy and recognize Dr. Sandberg's pioneering work," says Sallye Wolf, executive director of the Dr. Marnie Rose Foundation. "Dr. Giuseppe Colasurdo, president of UTHealth, and Dr. Sandberg, an honorary board member of the foundation, have a strong relationship with the Rose family. It is only fitting that the Dr. Marnie Rose Professorship in Pediatric Neurosurgery be awarded to Dr. Sandberg. His innovative research and care for children affected by brain tumors honors Marnie's passion for helping children and the Foundation's commitment to brain cancer research."

Dr. Sandberg has pioneered innovative treatment approaches for malignant pediatric brain tumors. He was principal investigator of a recently completed pilot clinical trial investigating, for the first time in humans, direct delivery of chemotherapy into the fourth ventricle of the brain. The trial's promising results have led to a new methotrexate dose-escalation study available only at Children's Memorial Hermann Hospital in collaboration with Mischer Neuroscience Institute.

"The courage of our patients and their families inspires us on a daily basis to provide the best care available for pediatric brain tumors," says Dr. Sandberg, who is co-director of the combined Pediatric Brain Tumor Program at Children's Memorial Hermann Hospital and The University of Texas MD Anderson Cancer Center. "The support we've received from the Dr. Marnie Rose Foundation

will contribute to the discovery of new and better ways to prevent, diagnose and treat childhood brain tumors. I'm honored to be the recipient of the first Dr. Marnie Rose Professorship in Pediatric Neurosurgery."

Barbara J. Stoll, M.D., dean of McGovern Medical School and the H. Wayne Hightower Distinguished Professor, expressed her gratitude to the Rose family for their generosity. "I am delighted that Dr. Sandberg, a nationally known pediatric neurosurgeon and neuroscientist, is the inaugural Dr. Marnie Rose Professor," Dr. Stoll says. "We are very grateful to the Rose family for their gift and for their vision. Dr. Marnie Rose was an extraordinary young physician. We are honored to have a professorship in her memory at our school. Endowed professorships recognize and support outstanding faculty. They are important to academic health centers because they help us recruit and retain the most talented faculty in the country."

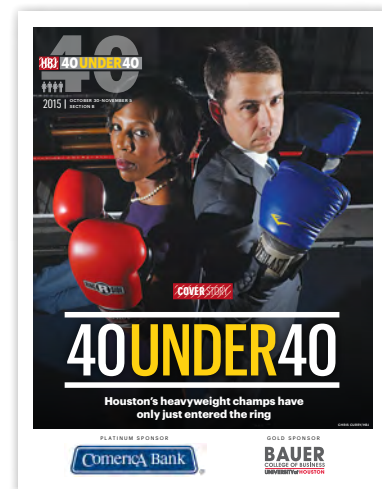### Dr. Manish Shah Named to *Houston Business Journal's* 40 Under 40



**MANISH N. SHAH, M.D.**  
Director, Pediatric Spasticity and Movement Disorder Surgery; Assistant Professor, Department of Pediatric Surgery, McGovern Medical School at UTHealth

Manish N. Shah, M.D., a pediatric neurosurgeon affiliated with Children's Memorial Hermann Hospital and the Memorial Hermann Mischer Neuroscience Institute at the Texas Medical Center, has been named to the *Houston Business Journal's* 40 Under 40 Class of 2015.

The prestigious award annually recognizes 40 of the Greater Houston area's most prominent up-and-coming professionals under the age of 40. Honorees must be nominated and are chosen by judges based on leadership, a track record of overcoming challenges and their community involvement. Nearly 400 professionals were nominated for



the 2015 award, according to the *Houston Business Journal*.

Dr. Shah directs the Texas Comprehensive Spasticity Center at McGovern Medical School, Children's Memorial Hermann Hospital and Mischer Neuroscience Institute. He is also director of pediatric spasticity and movement disorder surgery and runs a laboratory where researchers use advanced neuroimaging techniques to investigate basic brain function in children.

"I am proud to be recognized along with so many respected individuals in the Houston area," Dr. Shah says. "On a daily basis, I have the privilege of helping children achieve a better quality of life despite having a frightening and often debilitating neurological disease. That is reward enough. To be recognized for that work is an exceptional honor."

Dr. Shah is an assistant professor in the department of Pediatric Neurosurgery at McGovern Medical School and the leading neurosurgeon in the area for selective dorsal rhizotomy. He is fellowship-trained in pediatric neurosurgery, with special expertise in the surgical management of spasticity and dystonia in children, and performs selective dorsal rhizotomies and baclofen pump placement using advanced techniques. An expert in pediatric epilepsy, craniofacial surgery and craniocervical spine surgery, Dr. Shah was recruited from Washington University in St. Louis after completing his fellowship

at St. Louis Children's Hospital under world-renowned pediatric neurosurgeon Tae Sung Park, M.D.

He received his undergraduate degree from Princeton University and his medical degree from Vanderbilt University School of Medicine in Nashville, Tennessee. As a resident in neurological surgery at Washington University in St. Louis, Dr. Shah was awarded the department of Neurosurgery's Medical Student Teaching Award and the department's Annual Resident Research Symposium Research Award.

"Dr. Shah is an extraordinarily gifted physician who is bringing innovative treatments to our community and who will be a national leader in the field of pediatric neurosurgery," says David I. Sandberg, M.D., FAANS, FACS, FAAP, director of pediatric neurosurgery at Children's Memorial Hermann Hospital, Mischer Neuroscience Institute and McGovern Medical School. "I feel very fortunate to have the opportunity to work alongside Dr. Shah each day. It's a credit to our city and our medical institutions to attract individuals of his caliber."

The 40 Under 40 honorees were profiled in a special edition of the *Houston Business Journal* released last October.

### Seven Pediatric Neuroscience Specialists Named to Top Doctors Lists for 2015

Seven physicians affiliated with Children's Memorial Hermann Hospital, the Memorial Hermann Mischer Neuroscience Institute at the Texas Medical Center and McGovern Medical School at UTHealth were named to *Houstonia* magazine's 2015 listing of Top Doctors in Houston. Physicians named to the list were selected based on nominations solicited from nearly 16,000 medical professionals practicing in eight counties in the Greater Houston area.

Pediatric neurosurgeons included on the *Houstonia* magazine list are David I. Sandberg, M.D., FAANS, FACS,



FAAP, director of pediatric neurosurgery and an associate professor with joint appointments in the department of Pediatric Surgery and the Vivian L. Smith Department of Neurosurgery, and Manish N. Shah, M.D., director of the Texas Comprehensive Spasticity Center, director of pediatric spasticity and movement disorder surgery and an assistant professor in the department of Pediatric Surgery.

Pediatric neurologists named Top Doctors are Ian J. Butler, M.D., professor, director of child and adolescent neurology and Distinguished Chair in West Syndrome Research; Mary Kay Koenig, M.D., associate professor, director of the Mitochondrial Center of Excellence, co-director of the Tuberous Sclerosis Center of Excellence and Endowed Chair of Mitochondrial Medicine; Jeremy Lankford, M.D., assistant professor and director of the Child Neurology Residency Program; Pedro Mancias, M.D., Adriana Blood Professor of Pediatrics and assistant dean for diversity and inclusion; and Gretchen Von Allmen, M.D., associate professor in the department of Pediatrics, chief of pediatric epilepsy at Children's Memorial Hermann Hospital and director of the Pediatric Epilepsy Program.

Dr. Butler also was selected by his peers as Texas Super Doctor. Following an extensive nomination and research process conducted by Key Professional Media Inc., the results were published in the June 2015 issue of *Texas Monthly* magazine.



**DAVID I. SANDBERG, M.D., FAANS, FACS, FAAP**  
Director, Pediatric Neurosurgery, Mischer Neuroscience Institute; Associate Professor, Department of Pediatric Surgery and Vivian L. Smith Department of Neurosurgery; Dr. Mamie Rose Professorship in Pediatric Neurosurgery at McGovern Medical School at UTHealth



**MANISH N. SHAH, M.D.**  
Director, Pediatric Spasticity and Movement Disorder Surgery; Assistant Professor, Department of Pediatric Surgery, McGovern Medical School at UTHealth



**IAN J. BUTLER, M.D.**  
Director, Division of Child and Adolescent Neurology; Professor, Department of Pediatrics, McGovern Medical School at UTHealth



**MARY KAY KOENIG, M.D.**  
Associate Professor & Director, Mitochondrial Center of Excellence; Co-director, Tuberous Sclerosis Center of Excellence, Department of Pediatrics, McGovern Medical School at UTHealth



**JEREMY LANKFORD, M.D.**  
Assistant Professor, Department of Pediatrics, McGovern Medical School at UTHealth



**PEDRO MANCIAS, M.D.**  
Professor, Department of Pediatrics, McGovern Medical School at UTHealth



**GRETCHEN VON ALLMEN, M.D.**  
Associate Professor, Chief of Pediatric Epilepsy, Director of the Pediatric Epilepsy Program, Department of Pediatrics, McGovern Medical School



## SELECTED PUBLICATIONS

Arrey EN, Kerr ML, Fletcher S, Cox CS, Sandberg DI. Linear Non-Displaced Skull Fractures in Children: Who should be observed or admitted? *J Neurosurg Pediatrics*. 2015;4:1-6.

Bonfante E, Koenig MK, Adejumo RB, Perinjelil V, Riascos RF. The neuroimaging of Leigh syndrome: Case series and review of the literature. *Pediatr Radiol*. 2016 Jan 6. [Epub ahead of print]

Butler IJ, Lankford J, Hashmi S, Human MT. Biogenic amine metabolism in juvenile neurocardiogenic syncope with dysautonomia. *Ann Clin Transl Neurol*. 2014;1:251-57.

Chance A, Sandberg DI. Hydrocephalus in patients with closed neural tube defects. *Child Nerv Syst*. 2015 3(2):329-332.

Chevallier JA, Von Allmen GK, Koenig MK. Seizure semiology and EEG findings in mitochondrial diseases. *Epilepsia*. 2014 May;55(5):707-12. [Epub 2014 Mar 7]

Cykowski MD, Hicks J, Sandberg DI, Olar A, Bridge JA, Greipp PT, Navarro P, Kolodziej S, Bhattacharjee MB. Brain Metastasis of Crystal-Deficient, CD68-Positive Alveolar Soft Part Sarcoma: Ultrastructural Features and Differential Diagnosis. *Ultrastruc Pathol*. 2015;39(1):69-7.

Derksen A, Ritter C, Athar P, Kieseier BC, Mancias P, Hartung HP, Sheikh KA, Lehmann HC. Sural sparing pattern discriminates Guillain-Barré syndrome from its mimics. *Muscle Nerve*. 2014 Nov;50(5):780-4. [Epub 2014 Sep 24]

Debnam JM, Mahfouz YM, Ketonen L, Slopis JM, McCutcheon IE, Guha-Thakurta N. Multidetector CT with 3-dimensional volume rendering in the evaluation of the spine in patients with Neurofibromatosis type 1: a retrospective review in 73 patients. *Scoliosis* 9:15, 2014. [Epub 2014 Sep]

Dickerson AS, Pearson DA, Loveland KA, Rahbar MH, Filipek PA. Role of parental occupation in autism spectrum disorder diagnosis and severity. *Res Autism Spectr Disord*. 2014 Sep 1;8(9):997-1007.

Epilepsy Phenome/Genome Project Epi4K Consortium.1 Copy number variant analysis from exome data in 349 patients with epileptic encephalopathy. *Ann Neurol*. 2015 Aug;78(2):323-8. [Epub 2015 Jul 1]

EuroEPINOMICS-RES Consortium; Epilepsy Phenome/Genome Project Epi4K Consortium.1 De novo mutations in synaptic transmission genes including DNMT1 cause epileptic encephalopathies. *Am J Hum Genet*. 2014 Oct 2;95(4):360-70. [Epub 2014 Sep 25]

Fakhri A, Shah MN, Goyal MS. Advanced Imaging of Chiari 1 Malformations. *Neurosurg Clin N Am*. 2015 Oct;26(4):519-26.

Ghali MG, Srinivasan VM, Jea A, Slopis JM, McCutcheon IE. Neurofibromas of the phrenic nerve: a case report and review of the literature. *World Neurosurg*. 2015 Dec 20;pii:S1878-8750(15)01783-0.

Hecht JT, Bodensteiner JB, Butler IJ. Neurologic Manifestations of Achondroplasia. *Handbook of Clinical Neurology: Neurologic Aspects of Systemic Disease Part I*. Eds: J. Biller and J.M. Ferro, Elsevier, Philadelphia, PA. Vol. 119 (3rd Series):551-63, 2014.

Hope OA, Lankford J. Best Practices in Neurological Care: Epilepsy. *Future Medicine*. 2014 Feb;6-30.

Jeter CB, Patel SS, Morris JS, Chuang AZ, Butler IJ, Sereno AB. Oculomotor executive function abnormalities with increased tic severity in Tourette syndrome. *J Child Psychol Psychiatry*. 2015;56(2):193-202.

Khiewvan B, Macapinlac HA, Lev D, McCutcheon IE, Slopis JM, Al Sanna G, Wei W, Chuang HH. The value of <sup>18</sup>F-FDG PET/CT in the management of malignant peripheral nerve sheath tumors. *Eur J Nucl Med Mol Imaging*. 2014 Sept;41(9):1756-66. [Epub 2014 Apr]

Kivlin CM, Watson KL, Al Sanna GA, Belousov R, Ingram DR, Huang KL, May CD, Bolshakov S, Landers SM, Kalam AA, Slopis JM, McCutcheon IE, Pollock RE, Lev D, Lazar AJ, Torres KE. Poly (ADP) Ribose Polymerase Inhibition: A Potential Treatment of Malignant Peripheral Nerve Sheath Tumor. *Cancer Biol Ther*. 2015 Dec 9;e1108486. [Epub ahead of print]

Lalani SR, Liu P, Rosenfeld JA, Watkin LB, Chiang T, Leduc MS, Zhu W, Ding Y, Pan S, Vetrini F, Miyake CY, Shinawi M, Gambin T, Eldomery MK, Akdemir ZH, Emrick L, Wilnai Y, Schelley S, Koenig MK, Memon N, Farach LS, Coe BP, Azamian M, Hernandez P, Zapata G, Jhangiani SN, Muzny DM, Lotze T, Clark G, Wilfong A, Northrup H, Adesina A, Bacino CA, Scaglia F, Bonnen PE, Crosson J, Duis J, Maegawa GH, Coman D, Inwood A, McGill J, Boerwinkle E, Graham B, Beaudet A, Eng CM, Hanchard NA, Xia F, Orange JS, Gibbs RA, Lupski JR, Yang Y. Recurrent Muscle Weakness with Rhabdomyolysis, Metabolic Crises, and Cardiac Arrhythmia Due to Bi-allelic TANGO2 Mutations. *Am J Hum Genet*. 2016 Feb 4;98(2):347-57. [Epub 2016 Jan 21]

Lankford J, Numan M, Hashmi S, Gourishankar A, Butler I. Cerebral blood flow during HUTT in young patients with orthostatic intolerance. *Clin Auto Res*. 2015;25:277-84.

Luna B, Bhatia S, Yoo C, Felty Q, Sandberg DI, Duchowny M, Khatib Z, Miller I, Ragheb J, Prassana J, Roy D. Proteomic and Mitochondrial Genomic Analyses of Pediatric Brain Tumors. *Molec Neurobiol*. 2015;52(3):1341-6.

Mosquera RA, Koenig MK, Adejumo RB, Chevallier J, Hashmi SS, Mitchell SE, Pacheco SE, Jon C. Sleep disordered breathing in children with mitochondrial disease. *Pulmonary Medicine*. 2014;article ID 467576, 8 pages.

Numan MT, Alnajjar R, Lankford J, Gourishankar A, Butler I. Cardiac asystole during head up tilt (HUTT) in children and adolescents: Is this benign physiology? *Pediatr Cardiol*. 2015;36:140-45.

Papanna R, Moise KJ Jr, Mann LK, Fletcher S, Schniederjan R, Bhattacharjee MB, Stewart RJ, Kaur S, Prabhu SP, Tseng SC. Cryopreserved human umbilical cord patch for in-utero spina bifida repair. *Ultrasound Obstet Gynecol*. 2016 Feb;47(2):168-76.

Parikh S, Goldstein A, Koenig MK, Scaglia F, Enns GM, Saneto R, et al. Practice Patterns of Mitochondrial Disease Physicians in North America. Part 1: Diagnostic and Clinical Challenges. *Mitochondrion*. 2014;14:26-33.

Parikh S, Goldstein A, Koenig MK, Scaglia F, Enns GM, Saneto R, Anselm I, Cohen BH, Falk MJ, Greene C, Gropman AL, Haas R, Hirano M, Morgan P, Sims K, Tarnopolsky M, Van Hove JL, Solfe L, DiMauro S. Diagnosis and management of mitochondrial disease: a consensus statement from the Mitochondrial Medicine Society. *Genetics in Medicine*. 2014.

Rebsamen M, Pochini L, Stasyk T, de Araújo ME, Galluccio M, Kandasamy RK, Snijder B, Fauster A, Rudashevskaya EL, Bruckner M, Scorzoni S, Filipek PA, Huber KV, Bigenzahn JW, Heinz LX, Kraft C, Bennett KL, Indiveri C, Huber LA, Superti-Furga G. SLC38A9 is a component of the lysosomal amino acid sensing machinery that controls mTORC1. *Nature*. 2015 Mar 26;519(7544):477-81. [Epub 2015 Jan 7]

Sandberg DI. Endoscopic Resection of Intraventricular Brain Tumors in Children. *World Neurosurgery*. 2015 [Epub ahead of print]

Sandberg DI, Rytting M, Zaky W, Kerr M, Ketonen L, Kundu U, Moore BD, Yang G, Hou P, Sitton C, Cooper LJ, Gopalakrishnan V, Lee DA, Thall PF, Khatua S. Methotrexate Administration Directly into the Fourth Ventricle in Children with Malignant Fourth Ventricle Brain Tumors: A Pilot Clinical Trial. *J Neurooncol*. 2015;125(1):133-141.

Sandberg DI, Kerr ML. Ventricular Access Device Placement in the Fourth Ventricle to Treat Malignant Fourth Ventricle Brain Tumors: Technical Note. *Childs Nerv Syst*. 2015 Nov 23. [Epub ahead of print]

Shinnar S, Cnaan A, Hu F, Clark P, Dlugos D, Hirtz DG, Masur D, Mizrahi EM, Moshé SL, Glauser TA, Childhood Absence Epilepsy Study Group.<sup>1</sup> Long-term outcomes of generalized tonic-clonic seizures in a childhood absence epilepsy trial. *Neurology*. 2015 Sep 29;85(13):1108-14. [Epub 2015 Aug 26]

Simard-Tremblay E, Berry P, Cook WB, Owens A, Mazzanti M, Novotny EJ, Saneto RP. High-fat diets and seizure control in myoclonic-astatic epilepsy: A single center's experience. *Seizure*. 2015 Feb;25:184-6. [Epub 2014 Oct 23]

Soler-Alfonso C, Enns GM, Koenig MK, Saavedra H, Bonfante-Mejia E, Northrup H. Identification of HIBCH gene mutations causing autosomal recessive Leigh syndrome: a gene involved in valine metabolism. *Pediatric Neurology*. 2015 March;52(3):361-65.


Subbiah V, Bupathi M, Kato S, Livingston A, Slopis J, Anderson PM, Hong DS. Clinical next-generation sequencing reveals aggressive cancer biology in adolescent and young adult patients. *Oncoscience* 2(7):646-58, 2015. [Epub 2015 July]

Szafranski P, Von Allmen GK, Graham BH, Wilfong AA, Kang SH, Ferreira JA, Upton SJ, Moeschler JB, Bi W, Rosenfeld JA, Shaffer LG, Wai Cheung S, Stankiewicz P, Lalani SR. 6q22.1 microdeletion and susceptibility to pediatric epilepsy. *Eur J Hum Genet*. 2015 Feb;23(2):173-9. [Epub 2014 May 14]

Theeler BJ, Ellezam B, Yust-Katz S, Slopis JM, Loghin ME, de Groot JF. Prolonged survival in adult neurofibromatosis type I patients with recurrent high-grade gliomas treated with bevacizumab. *J Neurol*. 2014 Aug;261(8):1559-64. [Epub 2014 May 25]

<sup>1</sup> Gretchen Von Allmen, M.D., is listed as an author in the first, second and third papers under the Childhood Absence Epilepsy Study Group and the Epilepsy Phenome/Genome Project Epi4K Consortium.





Memorial Hermann Health System  
7737 Southwest Freeway  
Houston, TX 77074

[childrens.memorialhermann.org/neuro](http://childrens.memorialhermann.org/neuro)  
832.325.7242

Nonprofit Org.  
U.S. POSTAGE  
**PAID**  
Permit No. 3156  
Houston, TX